

LASIK Flap Characteristics Using the Moria M2 Microkeratome With the 90- μ m Single Use Head

Ioannis M. Aslanides, MD, PhD; Nikolaos S. Tsiklis, MD; Nikolaos I. Astyrakakis, OD; Ioannis G. Pallikaris, MD, PhD; Mirko R. Jankov, MD

ABSTRACT

PURPOSE: To evaluate the accuracy and consistency of corneal flap thickness, horizontal diameter, and hinge size with the Moria M2 90- μ m single use head.

METHODS: Fifty-two myopic patients (104 eyes), mean age 32.6 years, underwent bilateral LASIK with a superior hinged flap using the Moria M2 microkeratome (90- μ m single use head). Prospective evaluation included flap thickness (subtraction method), diameter, hinge size, interface particles, intraoperative complications, and visual recovery.

RESULTS: The mean preoperative spherical equivalent refraction was -5.72 ± 2.59 diopters (D) (range: -2.88 to -10.75 D) and -5.84 ± 2.73 D (range: -3.13 to -9.38 D) for right and left eyes, respectively. The mean preoperative central corneal thickness was 548 ± 24 μ m and 547 ± 25 μ m for right and left eyes, respectively. The mean preoperative steepest K was 44.12 ± 1.28 D and 44.41 ± 1.27 D for right and left eyes, respectively. Corneal diameter (white-to-white) was 12 ± 0.4 mm and 11.9 ± 0.4 mm for right and left eyes, respectively. The mean postoperative flap thickness was 109 ± 18 μ m (range: 67 to 152 μ m) and 103 ± 15 μ m (range: 65 to 151 μ m) for right and left eyes, respectively. The mean postoperative flap diameter was 9.4 ± 0.3 mm (expected mean according to the nomogram given by the company was 9.5 mm). The mean postoperative hinge chord was 4.4 ± 0.4 mm (expected mean 4.2 mm). No interface particles were detected on slit-lamp examination.

CONCLUSIONS: The Moria M2 90- μ m single use head is safe with reasonable predictability for LASIK flap creation. [*J Refract Surg.* 2007;23:45-49.]

Laser in situ keratomileusis (LASIK) is a common refractive surgery for the correction of myopia, hyperopia, and astigmatism.¹ The advantages of the procedure² (fast, painless recovery of vision, lack of subepithelial haze) are mainly due to the creation of a corneal flap. At the same time, the use of a microkeratome to create a corneal flap increases the risks of intraoperative complications such as free cap, irregular buttonhole, or incomplete flap.³⁻¹¹

Many different microkeratomes and corresponding heads can be used to create the corneal flap.¹ The most popular microkeratomes for LASIK are based on the oscillating blade principle. The Moria M2 (Antony, France) is a popular compact automated microkeratome with mechanical stop designed for maximum safety.

This prospective study evaluates the accuracy and consistency of corneal flap thickness, horizontal diameter, and hinge size produced by the Moria M2 90- μ m single use head, as well as visual acuity on postoperative days 1 and 3, which is related to both the microkeratome cut and the excimer laser ablation.

PATIENTS AND METHODS

This prospective study included 52 myopic patients (24 men and 28 women, 104 eyes) with a mean age of 32.6 ± 8.8 years (range: 19 to 53 years). Preoperative measurements included uncorrected visual acuity (UCVA), best spectacle-corrected visual acuity, manifest and cycloplegic refraction, slit-lamp examination with fundus evaluation, corneal topography (C-Scan; Technomed, Baesweiler, Germany), ultrasonic pachymetry (Pac Scan 300P; Sonomed, Lake Success, NY), and corneal diameter (white-to-white distance; Canon autore-

From VEIC - Vardinoyiannion Eye Institute of Crete, School of Medicine, University of Crete, Greece.

The authors have no financial or proprietary interest in the materials presented herein.

Correspondence: Mirko R. Jankov, MD, VEIC - Vardinoyiannion Eye Institute of Crete, University of Crete, PO Box 1352, 71110 Voutes, Heraklion Crete, Greece. Tel: 381 11 245 5759; Fax: 30 2810 394 653; E-mail: visioncare@mac.com

Received: June 10, 2005

Accepted: April 11, 2006

Posted online: August 31, 2006

fractometer; Canon Medical Systems, Irvine, Calif). All pachymetry measurements were done by the same individual (A.N.I.).

The mean preoperative spherical equivalent refraction was -5.72 ± 2.59 diopters (D) (range: -2.88 to -10.75 D) in the right eye and -5.84 ± 2.73 D (range: -3.13 to -9.38 D) in the left eye. The mean preoperative steepest K was 44.12 ± 1.28 D in the right eye and 44.41 ± 1.27 D in the left eye. Mean corneal thickness was 548 ± 24 μm (range: 491 to 595 μm) in the right eye and 547 ± 25 μm (range: 490 to 603 μm) in the left eye, whereas mean white-to-white corneal diameter in the right eye was 12 ± 0.4 mm (range: 11 to 12.5 mm) and 11.9 ± 0.4 mm (range: 11 to 12.5 mm) in the left eye.

All patients underwent primary LASIK in both eyes by the same surgeon (A.I.M.) using the Allegretto Wave excimer laser (WaveLight Technologies, Erlangen, Germany). Inclusion criteria were myopia between -2.00 and -10.00 D, <3.00 D of corneal astigmatism, (manufacturer's guideline), and age ≥ 18 years. Exclusion criteria were history of corneal dystrophy or herpetic eye disease, topographic evidence of keratoconus or warp-age from contact lenses, corneal scarring, glaucoma, severe dry eye, and collagen vascular diseases.

LASIK procedures were performed in a standardized manner. One drop of proparacaine 0.5% (Alcaine; Alcon, Ft Worth, Tex) was instilled in each eye 5 minutes and just before the procedure. This was followed by a povidone-iodine (Betadine; Lavipharm, Paenia, Greece) preparation of the eyelids. Eyelashes were isolated by a drape, and a speculum with suction was placed into the operative eye. The cornea was marked with a corneal marker using gentian violet staining.

The microkeratome settings (suction ring, flap stop) were chosen according to the steepest K (manufacturer's nomogram), aiming for the maximum flap diameter. The Moria M2 90- μm single use head was used for a desired cut depth of 120 μm and a superior hinge. The standard speed of pass ("speed 2": 15,000 rpm, 2 seconds of cutting time) was used in all cases. One single use head was used in both eyes of each patient (the right eye was always done first), and the head was discarded upon completion of the procedure. After the microkeratome pass, the flap was lifted and central ultrasound pachymetry of the residual stromal bed was performed. Three measurements were taken and the mean value was subtracted from the preoperative corneal thickness. This difference was considered the flap thickness (subtraction pachymetry). After performing the laser ablation, the flap was floated back into position, and the stromal bed was irrigated with balanced salt solution. Flap alignment was checked using gentian violet premarkings on the cornea, and a striae test was performed to ensure proper flap adherence.

Using one drop of prednisolone acetate 1%, which clearly identified the outline of the flap furrow in its whole circumference, as well as the exact dimensions of the hinge chord, the measurements were taken with the use of a surgical caliper.

All patients were examined 60 minutes after surgery to check flap adherence. Postoperatively, they were given flurbiprofen sodium 0.03% drops (Ocufur; Allergan, Irvine, Calif) 4 times a day for 2 days, dexamethasone 0.1% + tobramycin 0.3% drops (Tobradex, Alcon) 4 times a day for 2 weeks, and sodium hyaluronate 0.18% drops (Vismed; TRB Chemedica, Newcastle under Lyme, United Kingdom) hourly for 1 month. Patients were instructed to wear protective eye shields at night and to return the following day and on postoperative day 3.

Statistical analysis was done using two-tailed Student *t* test for independent events and linear correlation.

RESULTS

The mean flap thickness for all eyes was 106 ± 17 μm , being 109 ± 18 μm (range: 67 to 152 μm) in the right eye and 103 ± 15 μm (range: 65 to 151 μm) in the left eye (Figs 1 and 2). The difference was not statistically significant ($P=.08$). The mean flap diameter was 9.4 ± 0.3 mm (range: 8.5 to 9.9 mm) and the mean hinge chord size was 4.4 ± 0.4 mm (range: 3.8 to 6 mm) (Figs 3 and 4).

The relationship between flap thickness and preoperative corneal thickness is demonstrated in Figure 5. A statistically significant correlation ($R^2=0.49$, $P<.0001$) showed that thicker corneas produce thicker flaps. None of the other tested parameters, such as age, flat K, steep K, or preoperative spherical equivalent refraction, showed any correlation with flap thickness.

No intraoperative complications occurred in this series. No interface particles were observed on slit-lamp examination. Mean UCVA (logMAR) on postoperative day 1 was 0.10 ± 0.09 (range: 0.30 to -0.08) and 0.05 ± 0.08 (range: 0.28 to -0.08) on postoperative day 3.

DISCUSSION

A crucial step during LASIK is the creation of a hinged corneal flap¹² due to the potential complication that may occur and cause the postponement of the procedure. The precision in reproducing flap thickness is significant when planning and performing LASIK surgery. A thin flap is generally desirable because it reveals a thicker stromal bed for the ablation, although it is more difficult to manipulate and more prone to complications such as folds or striae. Given the current recommendation of leaving at least 250 μm ^{4,13} of residual corneal tissue, a thinner flap allows the cor-

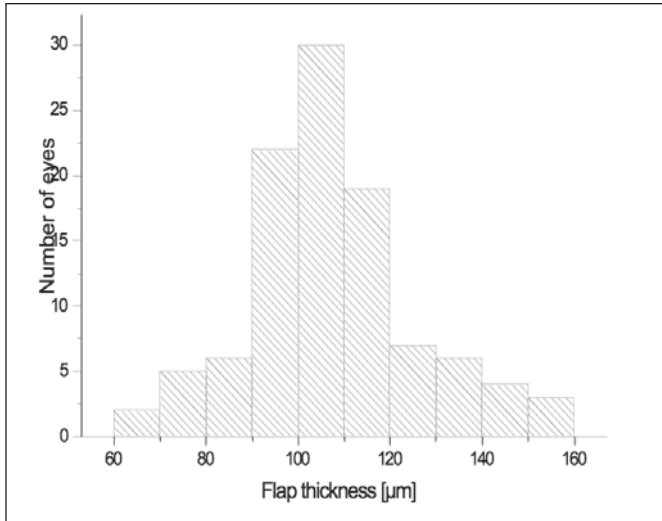


Figure 1. Distribution of flap thickness in 104 myopic eyes that underwent LASIK with the Moria M2 90-µm single use head.

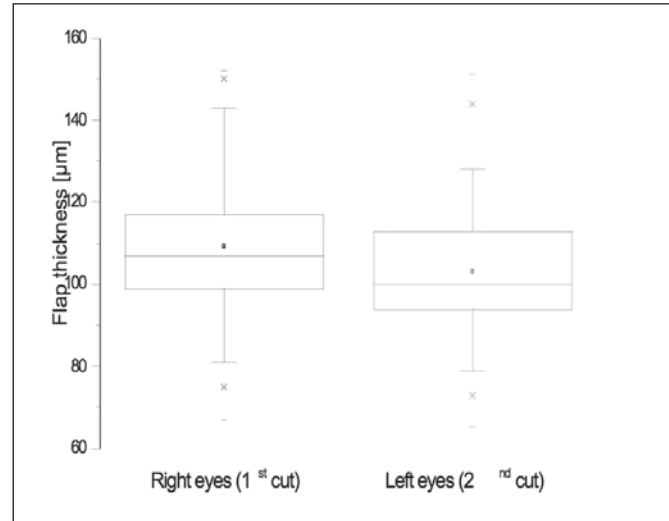


Figure 2. Comparison between flap thickness in first (right eyes) and second (left eyes) cuts in 104 myopic eyes that underwent LASIK with the Moria M2 90-µm single use head.

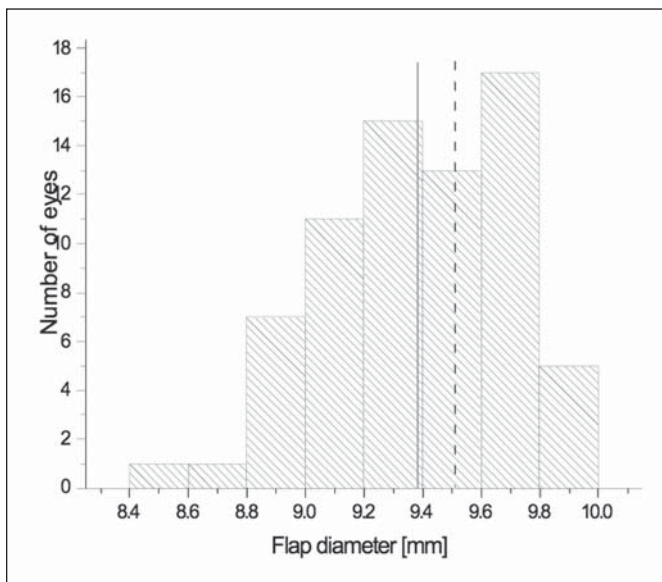


Figure 3. Distribution of flap diameter. The solid line represents the mean flap diameter for all eyes (9.4 mm) and the dashed line represents the expected diameter size (9.5 mm) according to the manufacturer's nomogram.

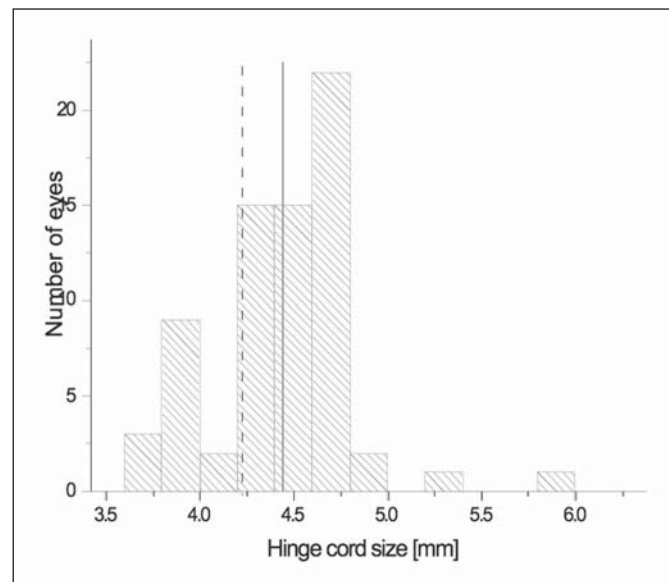


Figure 4. Distribution of hinge chord size (all eyes). The solid line represents the mean hinge chord size for all eyes (4.4 mm) and the dashed line represents the expected hinge chord size (4.2 mm) according to the manufacturer's nomogram.

rection of a larger amount of myopia. Therefore, a thin LASIK flap theoretically decreases the risk of corneal ectasia. On the other hand, the risk of flap irregularities, buttonholes, and epithelial defects may increase when thinner flaps are created.¹⁴ None of the patients in this series had any flap-related complication that required additional intervention.

The concept of a disposable microkeratome has been investigated and introduced in clinical practice by a number of manufacturers, but it was not until the first

encouraging results with the Moria M2 single use 130 head¹⁵ had it been shown that with an adequate design or plastic material choice, the increased flap-related complications with other disposable microkeratomes¹⁶ can be overcome.

This study evaluates the safety and efficiency of the Moria M2 90-µm single use head. The M2 90-µm single use head is a disposable unit made of plastic with several advantages over a conventional reusable microkeratome head. The most important is that a new

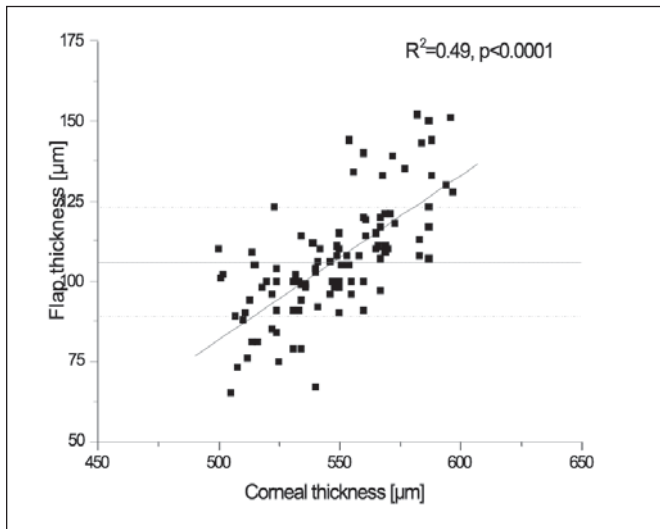


Figure 5. Relationship between flap thickness and preoperative corneal thickness. A statistically significant correlation shows thicker corneas to produce thicker flaps. The horizontal solid line shows mean flap thickness (106 μm) for all 104 eyes and the two horizontal dotted lines represent one standard deviation (SD) (17 μm). Flaps thicker and thinner than mean ± 1 SD have been observed in corneas thicker and thinner than 550 μm prior to surgery, respectively.

sterilized head is provided for every patient, which eliminates the need for sterilization by the surgical facility, in turn avoiding possible contamination by microbial pathogens and bacterial endotoxins. Moreover, it requires minimal technical manipulation as the microkeratome blade is pre-assembled with the disposable head, and being in a special package, it can be mounted without being touched.

In our study, the M2 single use head tended to cut less ($106 \pm 17 \mu\text{m}$) than the manufacturer expected ($120 \mu\text{m}$), although with a large range (65 to 152 μm). The M2 90- μm single use head seems to cut thinner flaps with smaller variability, comparable not only to other Moria heads^{14,15,17-21} but also to other microkeratomes with different heads.^{17,19,20,22-26}

The mean flap thickness in the second (left) eye was approximately 5.5% thinner than in the first (right) eye ($103 \pm 15 \mu\text{m}$ compared to $109 \pm 18 \mu\text{m}$), which is in agreement with other studies.^{17,19,20} Although no statistically significant difference ($P=.08$) was noted between the first (right eye) and second (left eye) cut, this may change with a larger number of eyes.

There was a trend showing that thicker corneas produce thicker flaps, which is comparable to other studies.^{20,22,23,25,27-30} Corneas as thin as 500 μm and as thick as 589 μm produced flaps with thicknesses between 90 and 133 μm . However, all flaps thicker than 133 μm were observed in corneas thicker than 550 μm , whereas all flaps thinner than 89 μm occurred in corneas that

were thinner than 550 μm prior to surgery. None of the other tested parameters, such as age, flat K, steep K, or preoperative spherical equivalent refraction, showed any correlation with flap thickness.

The mean flap diameter was $9.4 \pm 0.3 \text{ mm}$ and the mean hinge chord size was $4.4 \pm 0.4 \text{ mm}$, which were close to the expected values according to the manufacturer's nomogram (9.5 mm and 4.2 mm, respectively). A larger flap diameter with a small hinge allows a larger ablation zone, reduces the risk of ablating the hinge, and can be important when completing the procedure in cases with eccentric flaps. On the other hand, it increases the risk for intraoperative bleeding in cases of neovascularization of the peripheral cornea, as in chronic contact lens users.

Although several interspersed interface particles were observed in a previous confocal microscope study after LASIK with the Moria microkeratome,^{31,32} no interface particles were noted on slit-lamp examination in the present study.

The Moria M2 90- μm single use head seems to be safe and reasonably accurate (standard deviation 17 μm). However, intraoperative pachymetry should be done routinely, considering high range of flap thickness of as much as 95 μm , not only to prevent ectasia after LASIK but also for possible enhancement reoperation.

REFERENCES

- Pallikaris IG, Papatzanaki ME, Stathi EZ, Frenschock O, Georgiadis A. Laser in situ keratomileusis. *Lasers Surg Med.* 1990;10:463-468.
- El Danasoury MA, El Maghraby A, Klyce SD, Mehrez K. Comparison of photorefractive keratectomy with excimer laser in situ keratomileusis in correcting low myopia (from -2.00 to -5.50 D): a randomized study. *Ophthalmology.* 1999;106:411-420.
- Jacobs JM, Taravella MJ. Incidence of intraoperative flap complications in laser in situ keratomileusis. *J Cataract Refract Surg.* 2002;28:23-28.
- Tham VM, Maloney RK. Microkeratome complications of laser in keratomileusis. *Ophthalmology.* 2000;107:920-924.
- Lin RT, Maloney RK. Flap complications associated with lamellar refractive surgery. *Am J Ophthalmol.* 1999;127:129-136.
- Stulting RD, Carr JD, Thompson KP, Ferensowicz M, Furlong MT. Complications of laser in situ keratomileusis for the correction of myopia. *Ophthalmology.* 1999;106:13-20.
- Gimbel HV, Penno EE, van Westenbrugge JA, Ferensowicz M, Furlong MT. Incidence and management of intraoperative and early postoperative complications in 1000 consecutive laser in situ keratomileusis cases. *Ophthalmology.* 1998;105:1839-1847.
- Gimbel HV, van Westenbrugge JA, Penno EE, Ferensowicz M, Feinerman GA, Chen R. Simultaneous bilateral laser in situ keratomileusis; safety and efficacy. *Ophthalmology.* 1999;106:1461-1467.
- Knorz MC, Jendritza B, Hugger P, Liermann A. Complications after laser in situ keratomileusis (LASIK). *Ophthalmology.* 1999;96:503-508.
- Davidorf JM, Zaldivar R, Oscherow S. Results and complica-

- tions of laser in situ keratomileusis by experienced surgeons. *J Refract Surg.* 1998;14:114-122.
11. Asano-Kato N, Toda I, Hori-Komai Y, Takano Y, Tsubota K. Risk factors for insufficient fixation of microkeratome during laser in situ keratomileusis. *J Refract Surg.* 2002;18:47-50.
 12. Salah T, Waring GO III, El-Maghraby A, Moadel K, Grimm SB. Excimer laser in situ keratomileusis under a corneal flap for myopia of 2 to 20 diopters. *Am J Ophthalmol.* 1996;121:143-155.
 13. Walker MB, Wilson SE. Lower intraoperative flap complications rate with the Hansatome microkeratome compared to the Automated Corneal Shaper. *J Refract Surg.* 2000;16:79-82.
 14. Pietila J, Makinen P. Getting thinner flaps with Moria M2 microkeratome. Presented at: XXII Congress of the European Society of Cataract and Refractive Surgeons; September 18-22, 2004; Paris, France.
 15. Kanellopoulos AJ, Pe LH, Kleiman L. Moria M2 single use microkeratome head in 100 consecutive LASIK procedures. *J Refract Surg.* 2005;21:476-479.
 16. Pallikaris IG, Katsanevaki VJ, Panagopoulou SI. Laser in situ keratomileusis intraoperative complications using one type of microkeratome. *Ophthalmology.* 2002;109:57-63.
 17. Muallem MS, Yoo SY, Romano AC, Schiffman JC, Culbertson WW. Corneal flap thickness in laser in situ keratomileusis using the Moria M2 microkeratome. *J Cataract Refract Surg.* 2004;30:1902-1908.
 18. Jacobs BJ, Deutsch TA, Rubenstein JB. Reproducibility of corneal flap thickness in LASIK. *Ophthalmic Surg Lasers.* 1999;30:350-353.
 19. Solomon KD, Donnenfeld E, Sandoval HP, Al Sarraf O, Kasper TJ, Holzer MP, Slate EH, Vroman DT. Flap thickness accuracy: comparison of 6 microkeratome models. *J Cataract Refract Surg.* 2004;30:964-977.
 20. Miranda D, Smith SD, Krueger RR. Comparison of flap thickness reproducibility using microkeratomes with a second motor for advancement. *Ophthalmology.* 2003;110:1931-1934.
 21. Srivannaboon S. Flap analysis: critical point in laser in situ keratomileusis. *J Med Assoc Thai.* 2001;84:1317-1320.
 22. Shemesh G, Dotan G, Lipshitz I. Predictability of corneal flap thickness in laser in situ keratomileusis using three different microkeratomes. *J Refract Surg.* 2002;18:S347-S351.
 23. Giledi O, Mulhern MG, Espinosa M, Kerr A, Daya SM. Reproducibility of LASIK flap thickness using the Hansatome microkeratome. *J Cataract Refract Surg.* 2004;30:1031-1037.
 24. Kezirian GM, Stonecipher KG. Comparison of the IntraLase femtosecond laser and mechanical keratomes for laser in situ keratomileusis. *J Cataract Refract Surg.* 2004;30:804-811.
 25. Flanagan GW, Binder PS. Precision of flap measurements for laser in situ keratomileusis in 4428 eyes. *J Refract Surg.* 2003;19:113-123.
 26. Gailitis RP, Lagzdins M. Factors that affect corneal flap thickness with the Hansatome microkeratome. *J Refract Surg.* 2002;18:439-443.
 27. Choi YI, Park SJ, Song BJ. Corneal flap dimensions in laser in situ keratomileusis using the Innovatome automatic microkeratome. *Korean J Ophthalmol.* 2000;14:7-11.
 28. Yildirim R, Aras C, Ozdamar A, Bahcecioglu H, Ozkan S. Reproducibility of corneal flap thickness in laser in situ keratomileusis using the Hansatome microkeratome. *J Cataract Refract Surg.* 2000;26:1729-1732.
 29. Ucakhan OO. Corneal flap thickness in laser in situ keratomileusis using the Summit Krumeich-Barraquer microkeratome. *J Cataract Refract Surg.* 2002;28:798-804.
 30. Yi WM, Joo CK. Corneal flap thickness in laser in situ keratomileusis using an SCMD manual microkeratome. *J Cataract Refract Surg.* 1999;25:1087-1092.
 31. Javaloy Estan J, Vidal MT, Quinto A, Rojas V, Alio JL. Quality assessment model of 3 different microkeratomes through confocal microscopy. *J Cataract Refract Surg.* 2004;30:1300-1309.
 32. Perez-Gomez I, Efron N. Confocal microscopic evaluation of particles at the corneal flap interface after myopic laser in situ keratomileusis. *J Cataract Refract Surg.* 2003;29:1373-1377.