

# Acta Ophthalmologica

## Complications of intrastromal Corneal Ring Segments Implantation with Femtosecond laser for Channel Creation A Survey of 850 eyes with Keratoconus

Journal:	<i>Acta Ophthalmologica</i>
Manuscript ID:	ACTA-08-11-0724.R1
Manuscript Type:	Original Article
Date Submitted by the Author:	
Complete List of Authors:	Coskunseven, Efcan Kymionis, George; University of Crete, Ophthalmology Tsiklis, Nikolaos; Institute of vision and Optics, Ophthalmology Atun, Serife Arslan, Erbu Siganos, Charalampos jankov, Mirko Pallikaris, Ioannis
Keywords:	Intrastromal corneal ring segments, Complications, Femtosecond, Keratoconus

1  
2  
3  
4  
5  
6  
7  
8  
9  
10  
11  
12  
13  
14  
15  
16  
17  
18  
19  
20  
21  
22  
23  
24  
25  
26  
27  
28  
29  
30  
31  
32  
33  
34  
35  
36  
37  
38  
39  
40  
41  
42  
43  
44  
45  
46  
47  
48  
49  
50  
51  
52  
53  
54  
55  
56  
57  
58  
59  
60

# Complications of intrastromal Corneal Ring Segments Implantation with Femtosecond laser for Channel Creation A Survey of 850 eyes with Keratoconus

Efekan Coskunseven M.D.<sup>1</sup>, George D Kymionis M.D., Ph.D.<sup>2</sup>,  
Nikolaos S Tsiklis M.D., M.Sc., Ph.D.<sup>2</sup>, Serife Atun M.D.<sup>1</sup>,  
Ebru Arslan B.Sc.<sup>1</sup>, Charalambos S. Siganos MD, PhD<sup>2</sup>,  
Mirco Jankov M.D., Ph.D.<sup>3</sup>, Ioannis G Pallikaris M.D., Ph.D.<sup>2</sup>.

Dunya Eye Hospital, Istanbul, Turkey<sup>1</sup>

Institute of Vision and Optics, University of Crete, Greece<sup>2</sup>

Milos Klinika, Medical Academy-US Medical School, Belgrade, Serbia<sup>3</sup>

## Correspondence author

Nikolaos S. Tsiklis, M.D. M.Sc., Ph.D.

Institute of Vision and Optics

University Of Crete, Medical School

Department of Ophthalmology,

71003 Heraklion, Crete,

Greece.

Tel: ++302810.327316; Fax: ++302810.394653;

E-mail: [ntsiklis@hotmail.com](mailto:ntsiklis@hotmail.com)

The authors have no financial or proprietary interest in any materials or methods described  
herein

**ABSTRACT**

**Purpose:** To report the complications after implantation of intrastromal corneal ring segments (Keraring, Mediphacos, Belo Horizonte, Brazil) implantation in keratoconic eyes using a femtosecond laser (IntraLase, Advance Medical Optics, SA, USA) for channel creation.

**Setting:** Dunya Eye Hospital, Istanbul, Turkey.

**Methods:** Retrospective chart review of 531 patients (850 eyes) who had Kerraring, insertion using a femtosecond laser for channel creation. Intraoperative and postoperative complications were recorded.

**Results:** Intraoperatively, there were 22 (2.7%) cases of incomplete channel formation. The rest of the intraoperative complications were galvo lag error (system malfunction), [5 eyes, (0.6%)], endothelial perforation [5 eyes, (0.6%)] and incorrect entry of the channel [2 eyes, (0.2%)]. Postoperatively, there were eleven (1.3%) cases of segments' migration, 2 (0.2%) cases of corneal melting and one (0.1%) case of mild infection. The overall complication rate was 5.7% (49 cases out of 850 eyes).

**Conclusions:** Intracorneal ring segment implantation using a femtosecond laser for channel creation was related to a number of complications in this study. The most common complications were incomplete channel creation (intraoperatively) and segments' migration (postoperatively).

**Key words:** Intrastromal corneal ring segments, femtosecond laser, keratoconus

## INTRODUCTION

The implantation of intracorneal ring segments is a minimal invasive surgical procedure for keratoconic (Kymionis et al. 2007) or post-LASIK ectatic (Kymionis et al. 2006) corneas. Before the introduction of femtosecond laser technology, channel creation was accomplished manually using mechanical devices (Ruckhofer et al. 2001; Kanellopoulos et al. 2006; Zare et al. 2007). This step of the procedure related with a number of possible complications such as epithelial defects, anterior or posterior corneal perforations, infectious keratitis, asymmetric segment placement, corneal stromal edema around the incision, extension of the incision towards the central visual axis or the limbus and persistent incisional gapping (Ruckhofer et al. 2001; Kanellopoulos et al. 2006; Zare et al. 2007). Recently, channel creation is performed using the femtosecond laser, which can deliver energy accurately to a precise depth in a programmed way. Studies indicate that Intacs implantation using a femtosecond laser is a safe and effective procedure for treating keratoconic corneas (Ratkay-Traub et al. 2003; Carrasquillo et al. 2007; Ertan et al. 2006; Ertan & Bahadir 2007; Ertan et al. 2007; Coskunseven et al. 2008; Sugar 2002; Shabayek & Alio 2007). The femtosecond laser minimizes procedure time and decreases the risk of inflammation or infection.

There are several different types of intracorneal rings, with varying curvature, width and zone of implantation. The Keraring (Mediphacos, Belo Horizonte, Brazil) is a newly developed implantable intrastromal corneal ring segment made of PMMA and is characterized by a triangular cross section that induces a prismatic effect on the cornea. The Keraring's apical diameter is 5 mm and the flat basis width is 0.6 mm with variable thickness (0.15 to 0.30 mm thickness with 0.5 mm steps) and arc lengths (90°, 160° and 210°).

1  
2  
3 To our knowledge, this study is the first large clinical trial for the complications of this  
4 type of intracorneal ring segment using the femtosecond laser for channel creation in  
5  
6  
7  
8 keratoconic patients.  
9

## 10 METHODS

11  
12 Eight hundred fifty eyes (531 patients) with mild to moderate keratoconus underwent  
13 intrastromal corneal ring segment implantation (Keraring, Mediphacos, Belo Horizonte,  
14  
15 Brazil), using a Femtosecond laser (IntraLase, Advanced Medical Optics, Santa Ana,  
16  
17 California, USA) for channel creation. Prior to their operation, all patients gave informed  
18  
19 consent in adherence to institutional guidelines and the tenets of the Declaration of Helsinki.  
20  
21  
22  
23

24 A complete ophthalmologic examination was performed preoperatively, including  
25 uncorrected visual acuity (UCVA), best spectacle-corrected visual acuity (BSCVA), manifest  
26  
27 refraction, biomicroscopy, corneal topography [Orbscan IIz (Bausch & Lomb, Rochester,  
28  
29 NY), WaveLight Allegretto Topolyzer (WaveLight Laser Technologie, Erlangen, Germany)]  
30  
31 and endothelial cell density measurement with specular microscopy (Konan Specular  
32  
33 Microscope SP 9000 Noncon Robo Pachy Konan Medical Inc. Hyogo, Japan).  
34  
35  
36  
37

38 All patients had clear central corneas without scars and were contact lens intolerant.  
39  
40 Corneal thickness was at least 350  $\mu\text{m}$  at the tunnel location. Patients were excluded if any of  
41  
42 the following criteria applied after the preoperative examination: history of herpes, keratitis,  
43  
44 corneal dystrophies, diagnosed autoimmune disease, systemic connective tissue disease, acute  
45  
46 or grade IV keratoconus, and endothelial cell count of less than 1000 cells/ $\text{mm}^2$ .  
47  
48  
49

50 All procedures were performed under sterile conditions and topical anesthetic drops.  
51  
52 The Purkinje reflex was chosen as the central point and marked under the WaveLight  
53  
54 Allegretto Biomicroscope. A 5-mm marker was used to locate the exact ring channel. Corneal  
55  
56 thickness was measured intraoperatively using ultrasonic pachymetry (Sonogage, Cleveland,  
57  
58 Ohio, USA) along the ring location markings. Tunnel depth was set at 80% of the thinnest  
59  
60

1  
2  
3 corneal thickness on the tunnel location. Arc length and thickness were chosen according to  
4  
5 the manufacturer's nomogram. A 60 kHz femtosecond laser was used to create the ring  
6  
7 channels. The channel's inner diameter was set to 4.4 mm, and the outer diameter was 5.6  
8  
9 mm. The entry cut thickness was 1  $\mu\text{m}$ , and the ring energy used for channel creation was  
10  
11 1.30  $\mu\text{j}$ . The entry cut energy was 1.30  $\mu\text{j}$  and channel creation timing with the femtosecond  
12  
13 laser was 15 seconds. The intracorneal ring segments were implanted immediately after  
14  
15 channel creation, before the bubbles disappeared, as they revealed the exact tunnel location.  
16  
17 To avoid any injury to the incision area, the segment was directly implanted with the special  
18  
19 Keraring forceps.  
20  
21  
22  
23

24  
25 Mean patients' age was  $28.32 \pm 7.28$  (range, 18 to 44 years). Intraoperative and  
26  
27 postoperative complications were recorded.  
28

## 29 RESULTS

30  
31 The overall complication rate was 5.7% (49 cases).  
32

### 33 *Intraoperative complications*

34  
35 Incomplete channel formation occurred in 22 eyes (2.6%). In these eyes channels were  
36  
37 completed using a mechanical separator (Fig. 1).  
38  
39

40  
41 Galvanometer lag error (system malfunction) occurred in 5 cases (0.6%). In all cases  
42  
43 the error occurred two seconds before the completion of the incision. In two of the cases, the  
44  
45 procedure was restarted and the error occurred again at the exact same time. A 30° knife was  
46  
47 used then to complete the incision cut.  
48  
49

50  
51 There were 5 (0.6%) cases of endothelial perforation, which were present  
52  
53 intraoperatively as bubbles in the anterior chamber. In the first two patients, the ring was  
54  
55 initially displaced, moving into the anterior chamber. In the third and fourth case, we  
56  
57 recognized endothelial perforation during the channel creation. The channel was recreated  
58  
59 with a targeted depth of 30  $\mu\text{m}$  superficially than the original channel at the same time with  
60

1  
2  
3 the same vacuum. Edema was prevalent around the segment in these cases. In the last case the  
4 procedure was postponed for 1 month. Channel was recreated 90  $\mu\text{m}$  superficially to protect  
5  
6 the endothelium.  
7  
8

9  
10 Incorrect entry of the channel was a complication that occurred in two eyes (0.2%)  
11 while using the 150  $\mu\text{m}$  ring. A second channel was created using a mechanical separator.  
12  
13

14  
15 Vacuum loss occurred in one eye (0.1%). Vacuum was created again at the same  
16 conjunctival and corneal plan and the same corneal marking was used. Channel was  
17  
18 completed successfully at the same location and depth.  
19  
20

21  
22 The overall intraoperative complication rate was 4.1% (35 cases).  
23

### 24 *Postoperative complications*

25  
26 Segment's displacement was observed in 11 cases (0.8%). In seven cases the segments  
27 migrated in the channel. A suture was placed in these cases at the incision and removed two  
28 months later, preventing any further migration. In four eyes there was a superficial movement  
29 of the segments (Fig 2). All of them were removed before corneal melting occurred.  
30  
31

32  
33 Corneal melting (Fig. 3) was observed in 2 eyes (0.2%). In both cases corneal melting  
34 was noted above the segments because of the superficial placement of the rings and we  
35 performed a segment explantation with no further incidences.  
36  
37

38  
39 There was one (0.1%) case of infection following implantation. The patient  
40 experienced corneal abscess formation at the incision site that was treated with intense  
41 antibiotics.  
42  
43

44  
45 The overall postoperative complication rate was 1.6% (14 cases).  
46  
47

## 48 **DISCUSSION**

49  
50 The first study ever published about segment implantation (Intacs) with the use of  
51 femtosecond laser, Ratkay-Traub et al (2003) reported no intraoperative complications and  
52 minimal deposits in the channels of two eyes (12.5%). Carrasquillo et al (2007) also reported  
53  
54  
55  
56  
57  
58  
59  
60

1  
2  
3 no intraoperative complication during of femtosecond laser for channel creation.

4  
5 Postoperatively, 2 eyes (12.5%) developed corneal neovascularization and one eye (6.25%)  
6  
7 had a fungal infection seven months after surgery. Ertan et al, in three studies of segment  
8  
9 implantation with the use of femtosecond laser, had as the most common complications  
10  
11 epithelial plugs in 15.2% (Ertan et al. 2006) and 24.6% (Ertan et al. 2007) of eyes while  
12  
13 segments' migration occurred in three eyes (4.5%), (Ertan & Bahadir 2007).  
14  
15

16  
17 In the only comparative study regarding INTACS inserts using the femtosecond laser  
18  
19 or a mechanical spreader of Rabinowitz et al (2006) reported three (15%) patients had  
20  
21 significant epithelial defects and one patient (5 %) with a gram-positive infection during the  
22  
23 postoperative period in the femtosecond group. In the mechanical spreader group one patient  
24  
25 (5%) had INTACS extrusion due to superficial placement of the segment.  
26  
27

28  
29 In other studies after segment implantation with the traditional mechanical method  
30  
31 Kanellopoulos et al (2006) reported six (30%) cases of intracorneal ring segment movement  
32  
33 and one (5%) case of corneal melt. As the most common complication, Ruckhofer et al (2001)  
34  
35 reported corneal perforation in 4 (2.4%) eyes, while Zare et al (2007) reported segment  
36  
37 movement and exposure in 3 (10%) eyes.  
38  
39

40  
41 There are two studies regarding Kerrarings implantation using femtosecond laser for  
42  
43 channel creation; Coskunseven et al (2008) reported no intraoperative complication and 3  
44  
45 (6%) cases of segment migration in 50 eyes, while Shabayek and Alió (2007) had one eye  
46  
47 with infectious keratitis (4.8%) and eight eyes (38%) with incision opacification. In the  
48  
49 current study, we had 33 (4%) and 14 (1.6%) complicated cases during or immediately after  
50  
51 the procedure respectively. The discrepancy between the complication rates reported in the  
52  
53 literature, is mainly due to variations in the number of studied eyes (in the current study we  
54  
55 included 850 eyes) and difference in segments' characteristics (Intacs or Kerrarings).  
56  
57  
58  
59  
60



1  
2  
3 Incomplete channel creation and segments' migration were the most common intra-  
4 and postoperatively complication respectively. Incomplete channel formation occurred in 22  
5 (2.6%) eyes and all the procedures were completed with the use of a mechanical spreader. It is  
6 probably due to insufficient energy levels of the laser. This complication can be minimized by  
7 increasing the energy levels or by decreasing spot separation. Segments' displacement was  
8 observed in 11 cases (0.8%). In seven cases the segments migrate in the channel and a corneal  
9 suture placed at the incision site to prevent any further migration. In the other four eyes  
10 segments were moved superficially and were explanted before corneal melting occurred.

11  
12 Galvanometer lag error is a technical problem of the device and it was noticed in 5  
13 eyes (0.6%). The error is located at the memory system of the femtosecond which is unable to  
14 recall the operation center if this center is changed. In that case, a second channel has to be  
15 created next to the previous one. Additionally, the system does not have a separate incision  
16 cut program, therefore when the procedure is restarted, it begins with channel creation. To  
17 avoid the galvo error during channel creation, it is important to maintain the vacuum. If the  
18 galvo error does occur, the surgery should be postponed, and the second surgery should be  
19 performed with the same cone, (using a depth of 30  $\mu\text{m}$  superficially). In case that galvo error  
20 is experienced during incision creation, the incision should be continued with a blade, even if  
21 there is only one second remaining. With the blade, another channel can be created above or  
22 below of the original plane immediately, before the bubbles disappear so that it is easier to  
23 locate the channel.

24  
25 Endothelial perforation occurred in our study in five eyes (0.6%). It can be caused by  
26 incorrect preoperative pachymetry or deeper channels' creation. Femtosecond channel  
27 creation is very predictable but each cone has a 10-15  $\mu\text{m}$  standard deviation. To avoid the  
28 incidence of endothelial perforation, it is important to achieve correct and accurate  
29 pachymetry in a 5-mm optical zone at the implantation site. The reference point should be the  
30  
31  
32  
33  
34  
35  
36  
37  
38  
39  
40  
41  
42  
43  
44  
45  
46  
47  
48  
49  
50  
51  
52  
53  
54  
55  
56  
57  
58  
59  
60

1  
2  
3 point of thinnest pachymetry at the channel locations. Endothelial perforation can be  
4  
5 prevented by stopping channel creation as soon as the complication is recognized before the  
6  
7 incision. Femtosecond channel creation is circular, rather than raster, starting from the  
8  
9 central and continuing into the periphery. If bubbles are noted, and endothelial perforation  
10  
11 appears to be the case, surgery should be postponed for at least one month. Then a new  
12  
13 channel should be created 90  $\mu\text{m}$  superficially to protect the endothelium (Kanellopoulos et  
14  
15 al. 2006).  
16  
17  
18

19  
20 Incorrect entry of the channel occurred in 2 eyes (0.2 %). This complication may have  
21  
22 been caused because we do not use a channel starter. In case of a surgeon's delay, the bubbles  
23  
24 in the channel disappear. Therefore during the positioning of the segments a second channel  
25  
26 in another corneal depth can be formed.  
27  
28

29  
30 Postoperatively, corneal melting was noted in two eyes. Higher risk cases are those  
31  
32 with superficial placement of the ring, patients with very thin corneas or after incorrect  
33  
34 corneal pachymetry. In case of corneal melting, the ring has to be explanted immediately.  
35

36  
37 Vacuum loss occurred in one (0.1%) eye during channel creation. If vacuum loss  
38  
39 occurs during incision it is possible to create the vacuum again at the same conjunctival and  
40  
41 corneal plain, following the same marks to create the channel at the same location and depth.  
42  
43 In case we preferred to continue with a diamond knife, the bubbles in the channel would be  
44  
45 the reference point that would help us locate the channel more easily.  
46  
47

48  
49 The most severe and potentially sight threatening complications were endothelial  
50  
51 perforation (intraoperatively) corneal melting and infection (postoperatively), [0.9% (8  
52  
53 cases)].  
54

55  
56 Several potential limitations are apparent in this report, with the retrospective nature of  
57  
58 the study and the absence of a comparative mechanical group and the visual - refractive  
59  
60

1  
2  
3 outcomes of the participants to be the major reservations in order to conclude sufficient  
4  
5 results.  
6  
7

8           In conclusion, we describe several complications of intrastromal corneal ring segments  
9  
10 (Kerrrings) implantation with Femtosecond laser for channel creation. The most common  
11  
12 complications were incomplete channel creation (intraoperatively) and segments' migration  
13  
14 postoperatively.  
15  
16  
17  
18  
19  
20  
21  
22  
23  
24  
25  
26  
27  
28  
29  
30  
31  
32  
33  
34  
35  
36  
37  
38  
39  
40  
41  
42  
43  
44  
45  
46  
47  
48  
49  
50  
51  
52  
53  
54  
55  
56  
57  
58  
59  
60

For Peer Review

**REFERENCES**

1. Carrasquillo K, Rand J & Talamo JH (2007): Intacs for keratoconus and post-LASIK ectasia. Mechanical versus Femtosecond Laser–assisted channel creation. *Cornea* 26: 956–962.
2. Coskunseven E, Kymionis GD, Tsiklis NS, Atun S, Arslan E, Jankov MR & Pallikaris IG (2008): One-year results of intrastromal corneal ring segment implantation (KeraRing) using femtosecond laser in patients with keratoconus. *Am J Ophthalmol.* 145: 775-779.
3. Ertan A, Kamburoğlu G & Bahadır M (2006): Intacs insertion with the femtosecond laser for the management of keratoconus. One-year results. *J Cataract Refract Surg* 32: 2039–2042.
4. Ertan A & Bahadır M (2007): Topography-guided vertical implantation of Intacs using a femtosecond laser for the treatment of keratoconus. *J Cataract Refract Surg.* 33: 148-151.
5. Ertan A, Kamburoğlu G & Umit A (2007): Comparison of outcomes of 2 channel sizes for intrastromal ring segment implantation with a femtosecond laser in eyes with keratoconus. *J Cataract Refract Surg* 33: 648–653.
6. Kanellopoulos AJ, Pe LH, Perry HD & Donnenfeld ED (2006): Modified intracorneal ring segment implantations (INTACS) for the management of moderate to advanced keratoconus: efficacy and complications. *Cornea.* 25: 29-33.
7. Kymionis GD, Siganos CS, Tsiklis NS, Anastasakis A, Yoo SH, Pallikaris AI, Astyrakakis N & Pallikaris IG (2007): Long-term Follow-up of Intacs in Keratoconus. *Am J Ophthalmol* 143: 236-244.
8. Kymionis GD, Tsiklis NS, Pallikaris AI, Kounis G, Diakonis VF, Astyrakakis N & Siganos CS. (2006): Long-term follow-up of Intacs for post-LASIK corneal ectasia. *Ophthalmology* 113:1909-1917.

- 1  
2  
3 9. Rabinowitz YS, Li X, Ignacio TS & Maguen E. (2006): INTACS inserts using the  
4 femtosecond laser compared to the mechanical spreader in the treatment of keratoconus. J  
5 Refract Surg 22: 764-771.  
6  
7
- 8  
9  
10 10. Ratkay-Traub I, Ferincz IE, Juhasz T, Kurtz RM & Krueger RR (2003): First clinical  
11 results with the Femtosecond Neodymium-glass Laser in refractive surgery J Refract Surg.19:  
12 94-103.  
13  
14
- 15  
16  
17 11. Ruckhofer J, Stoiber J, Alzner E & Grabner G; Multicenter European Corneal  
18 Correction Assessment Study Group (2001): One year results of European Multicenter Study  
19 of intrastromal corneal ring segments. Part 2: complications, visual symptoms, and patient  
20 satisfaction. J Cataract Refract Surg. 27: 287-296.  
21  
22
- 23  
24  
25 12. Shabayek MH & Alió JL (2007): Intrastromal corneal ring segment implantation by  
26 femtosecond laser for keratoconus correction. Ophthalmology. 114: 1643-1652.  
27  
28
- 29  
30  
31 13. Sugar A (2002): Ultrafast (femtosecond) laser refractive surgery. Curr Opin  
32 Ophthalmol 13: 246–249.  
33  
34
- 35  
36  
37 14. Zare MA, Hashemi H & Salari, MR (2007): Intracorneal ring segment implantation  
38 for the management of keratoconus: Safety and efficacy. J Cataract Refract Surg 33: 1886–  
39 1891.  
40  
41  
42  
43  
44  
45  
46  
47  
48  
49  
50  
51  
52  
53  
54  
55  
56  
57  
58  
59  
60


**FIGURES**

Figure 1: Incomplete channel formation: bridges around the segment. In these eyes channels were completed with a mechanical separator.

Figure 2: Segment develops empty space around itself. This is the first step before the superficial movement of the ring.

Figure 3: Corneal melting above the ring segment due to superficial implantation.

For Peer Review




Incomplete tunnel formation: bridges around the segment. In these eyes tunnels were completed with a mechanical separator.  
99x75mm (300 x 300 DPI)

review

1  
2  
3  
4  
5  
6  
7  
8  
9  
10  
11  
12  
13  
14  
15  
16  
17  
18  
19  
20  
21  
22  
23  
24  
25  
26  
27  
28  
29  
30  
31  
32  
33  
34  
35  
36  
37  
38  
39  
40  
41  
42  
43  
44  
45  
46  
47  
48  
49  
50  
51  
52  
53  
54  
55  
56  
57  
58  
59  
60

1  
2  
3  
4  
5  
6  
7  
8  
9  
10  
11  
12  
13  
14  
15  
16  
17  
18  
19  
20  
21  
22  
23  
24  
25  
26  
27  
28  
29  
30  
31  
32  
33  
34  
35  
36  
37  
38  
39  
40  
41  
42  
43  
44  
45  
46  
47  
48  
49  
50  
51  
52  
53  
54  
55  
56  
57  
58  
59  
60

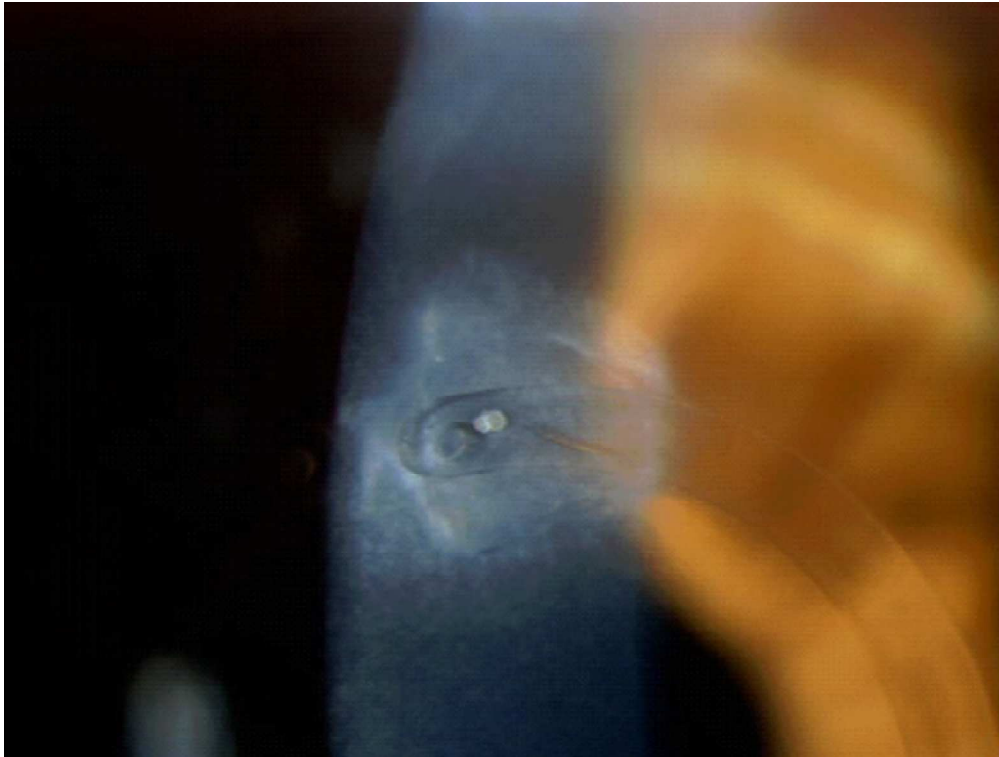


Segment develops empty space around itself. This is the first step before the superficial movement of the ring.  
489x369mm (300 x 300 DPI)

Review



1  
2  
3  
4  
5  
6  
7  
8  
9  
10  
11  
12  
13  
14  
15  
16  
17  
18  
19  
20  
21  
22  
23  
24  
25  
26  
27  
28  
29  
30  
31  
32  
33  
34  
35  
36  
37  
38  
39  
40  
41  
42  
43  
44  
45  
46  
47  
48  
49  
50  
51  
52  
53  
54  
55  
56  
57  
58  
59  
60



Corneal melting above the ring segment due to superficial implantation.  
569x429mm (300 x 300 DPI)

Review